

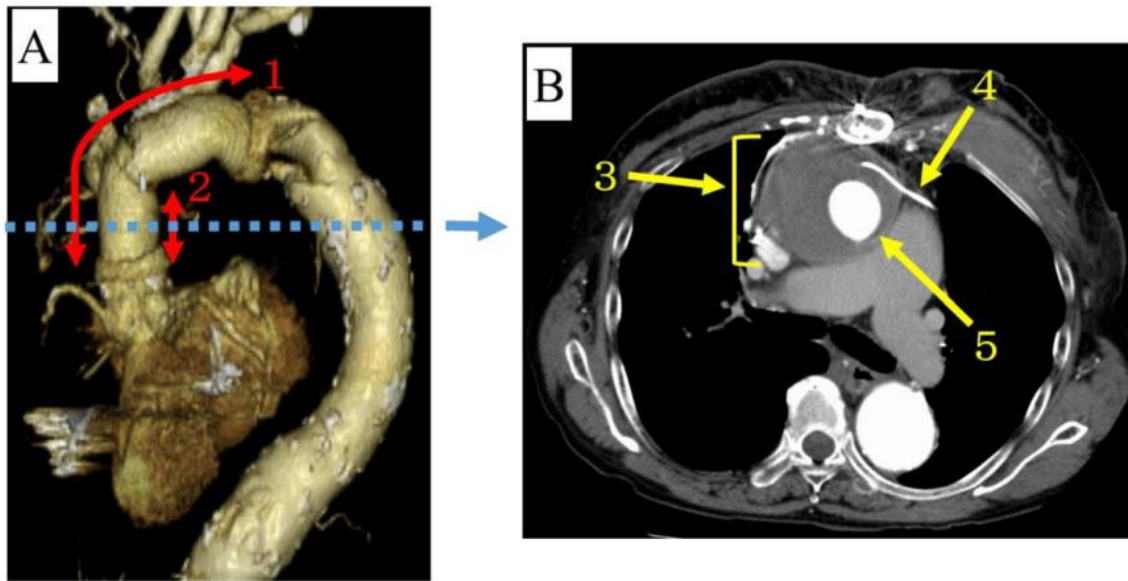Fig. 1 Enhanced computed tomography. **A:** 3D imaging from left anterior oblique; ①Aortic arch replacement on the first sternotomy. ②Ascending aorta replacement on the second sternotomy. **B:** Axial view; ③Periprosthetic vascular graft hematoma ④Lead on epicardium. ⑤Prosthetic vascular graft on ascending aorta

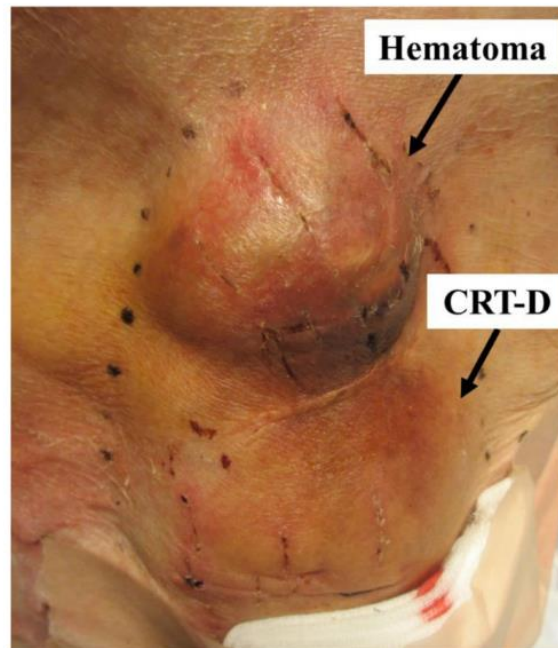


Fig. 2 The picture of hematoma around cardiac resynchronization therapy-defibrillator